

SKIN REPAIR PROPERTIES OF *ALOE VERA* IN ALBINO MICE

Mukesh Kumar¹, Neelmani², Nandjee Kumar³

^{1,2,3} Institute of Biochemistry, Magadh University, Bodhgaya, Bihar, (India)

ABSTRACT

The purpose of this study was to evaluate the effect of topical administration of Aloe vera on excision wound healing in mice. Mechanical skin lesion were used here to assess the efficacy of Aloe vera applied topically. Macroscopic and microscopic evaluation of skin lesions was performed. Excision wounds were made on the back of albino mice. Albino mice were divided into following groups, as control, and treatment. The control group did not receive any treatment. The wound tissues were removed on 6th and 12th day for histopathological analysis. Results showed that Aloe vera increased epithelialization and decreased inflammation but did not have any effect on percentage of wound contraction. The microscopic examination of the wound tissue collected and kept as control showed marked increase in collagen accumulation and fibroblast cell proliferation with the newly formed blood vessels. The fibroblast cell was still swollen, plumped and oval. Collagen fiber was also thin, fine and intermixes with the matrix. The wound healing property of Aloe vera gel has been attributed to Mannose-6-phosphate. Actually, glucomannan and plant growth hormone gibberellins interacts with growth factor receptors of fibroblast and stimulate its activity and proliferation for increases collagen synthesis in topical and oral administration of Aloe vera. The Aloe Vera administration influence collagen composition (more type III) and increased collagen cross linking for wound contraction and improving breaking strength. It also increases synthesis of hyaluronic acid and dermatan sulfate in the granulation tissue of a healing wound. It was concluded that Aloe vera can significantly stimulate epithelialization and reduce inflammation in full-thickness wounds in mice. These studies show that Aloe Vera demonstrate significant anti-inflammatory effects in mice dermal inflammation and wound-healing.

Keywords: *Aloe Vera, Epithelialization, Excision Wound, Wound Healing.*

I. INTRODUCTION

Wounds are physical injuries that result in an opening or break of the skin. Proper healing of wounds is essential for the restoration of disrupted anatomical continuity and disturbed functional status of the skin [1]. Wound healing is a complex process that involves a variety of processes such as inflammation, proliferation and remodeling. The process of wound healing is essential to prevent the invasion of damaged tissue by pathogens and to reform the damaged tissue [5]. Healing requires the collaborative efforts of many different tissues and cell lineages [10]. It involves platelet aggregation and blood clotting, formation of fibrin, an inflammatory response to injury, alteration in the ground substances, angiogenesis and re-epithelialization. Healing is not complete until the disrupted surfaces are firmly knit by collagen [2]. The basic principle of wound healing is to

minimize tissue damage and provide adequate tissue perfusion and oxygenation, proper nutrition and moist wound healing environment to restore the anatomical continuity and function of the affected part [11]. Wound healing involves the activity of an intricate network of blood cells, cytokines and growth factors which ultimately leads to the restoration to the normal condition of the injured skin or tissue [8].

Adverse effects from synthetic chemicals, the trend is shifting toward the use of herbal medicine [12]. Several herbal and natural products have been investigated for the promotion of wound healing [13]. *Aloe vera* (*Aloe barbadensis*) has long been used as an herbal medicine for healing skin wounds [14]. It has been reported that *Aloe vera* gel stimulated dermal wound healing in rats by increasing collagen and glycosaminoglycan synthesis [3]. *Aloe Vera* is a medicinal plant used traditionally due to its therapeutic properties such as wound-healing properties, immune modulatory, anti-inflammatory, antiviral, antibacterial and antioxidant activities [6]. The most common folk use of *Aloe vera* has been for the treatment of burn wounds and specifically to aid in the healing process, reduce inflammation, and tissue scarring. The juice was described by Dioscorides and used to treat wounds and mouth infections, soothe itching, and cure sores. It has been shown the activity of *Aloe* depends on the Acemannan content. Accordingly the greater the Acemannan content, the greater bioactivity and beneficial effect on skin care and wound healing. In fact, Acemannan is so important that the International *Aloe* Science Council has determined that if a product does not contain Acemannan it is not *Aloe vera*. Burn and wound healing effects of *Aloe vera* are very abundant with small quantity of solid material by providing essential micronutrients, anti-inflammatory and antimicrobial effects [9].

II. MATERIALS AND METHODS

2.1 Materials

2.1.1) Experimental Laboratory animals

Swiss Albino mice, weighing around 30-35g of approx. 8 weeks old, were obtained from animal house of Mahavir Cancer Institute and Research Centre, Patna, India. Food and water to mice were provided ad libitum (prepared mixed formulated food by the laboratory itself). The experimental animals were housed in conventional polypropylene cages in small groups. The mice were randomly assigned to control and treatment groups. The temperature in the experimental animal room was maintained at $22 \pm 2^{\circ}$ C with 12 h light/dark cycle.

Swiss albino mice was selected as the experimental animals, because of:

- a) Their physiological activity is almost similar to that of man (as 90% of their genes are similar to humans).
- b) Rapid rate of inbreeding.
- c) Small size.
- d) Early puberty (sexual maturity).
- e) Short gestation period.

2.1.2) Test chemical: Betadine

2.1.3) Plant material: - *Aloe vera* juice.

2.1) Methods

The study was carried out in following part:

2.2.1) Extraction of *Aloe vera* juice and preparation of working formula.

2.2.2) Creation of excision wound.

2.2.3) Treatment of wounds.

2.2.4) Estimation of wound healing.

2.2.5) Statistical analysis of the data.

III. RESULTS

3.1) 6th days

Histopathological analysis on 6th day of *Aloe vera* application on excision wound in albino mice.

Table-1

Parameter	NSS	Betadine	5% (v/v)	25% (v/v)	50% (v/v)	Analysis of result
Collageniza-tion	1.085± 0.036	1.15± 0.041	3.156± 0.139	2.200± 0.095	2.208± 0.037	Significant
Epithelializa-tion	1.127± 0.088	1.20± 0.190	1.328± 0.095	1.259± 0.066	1.255± 0.062	Non-Significant

Table-2

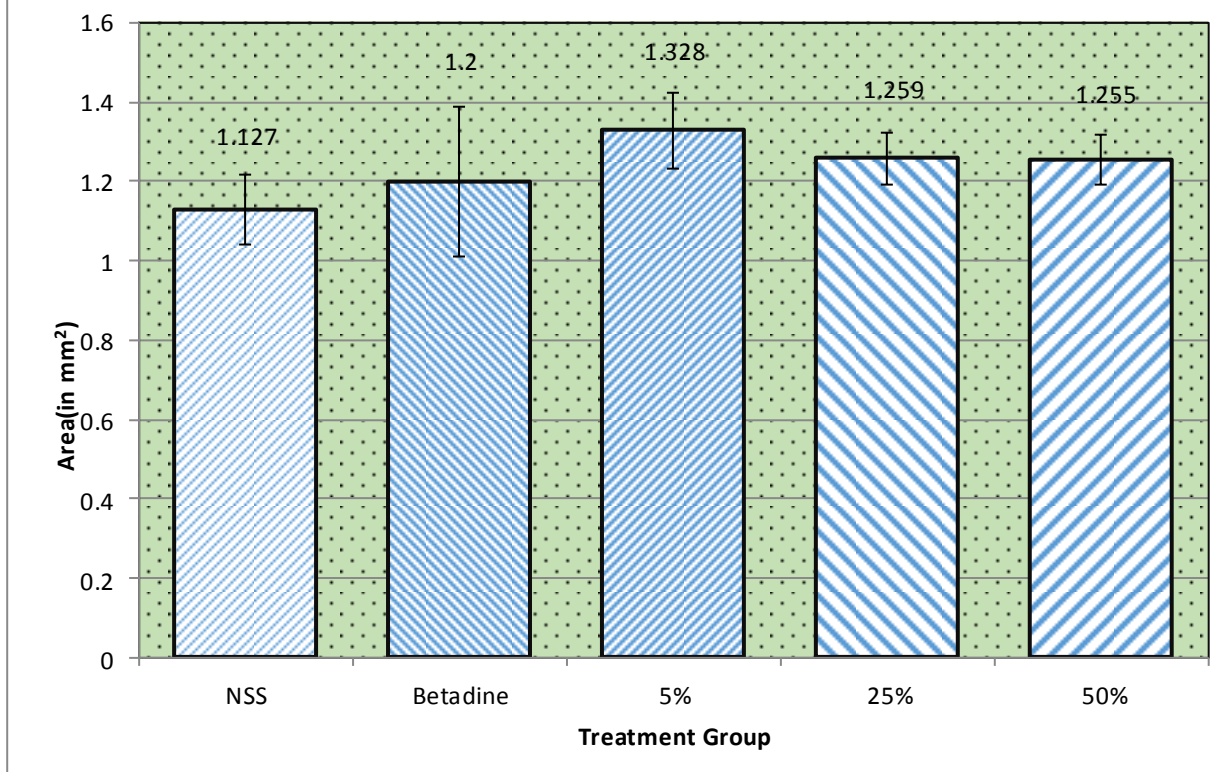
Analysis of variance showing effect of *Aloe vera* on histopathological finding in excision wound at 6th day.

Source of variance	df	Collagenization		
		SS	MS	F
Between group	4	17.48	4.369	54.31**
Errors	25	2.011	8.0439 E-02	
Total	29	19.49		

Table-3 Analysis of variance (ANOVA)

Source of variance	df	Epithelialization		
		SS	MS	F
Between group	4	0.1499	3.7472 E-02	0.5113
Errors	25	1.832	7.3284 E-02	
Total	29	1.982		

Fig-2 : Histopathological analysis of Epithelialiazation on 6th day of *Aloe Vera* application on excision wound in albano mice .



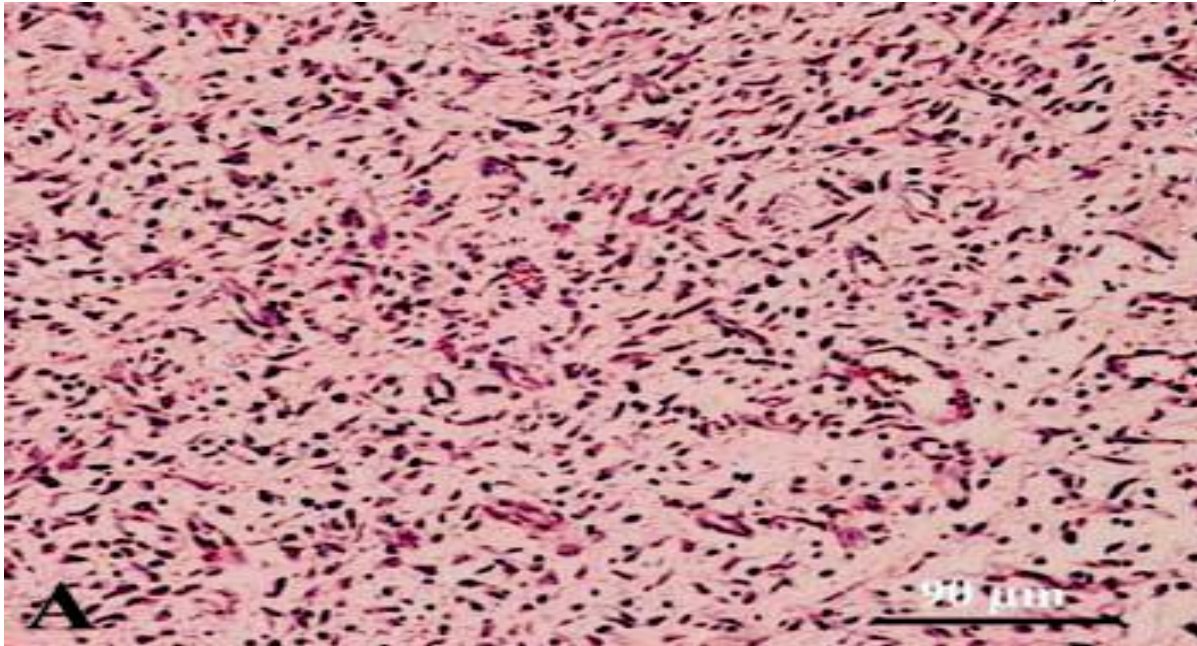


Fig 3: The untreated lesion on 6th day post-injury. The connective tissue of the dermis is highly infiltrated with inflammatory cells, the newly formed collagen fibers are unorganized and show a haphazardly distributed pattern. The glycosaminoglycan formation in the dermis is scanty (H&E, ×220).

On 6th day of wound creation, the microscopic examination of healing tissue collected and kept as control showed that majority of wound area invaded by granulation tissue comprising of macrophages, enlarged, swollen, oval fusiform fibroblast cell as well as proliferating endothelial cell and newly formed blood vessels. Fine and scanty collagen fibre were found to be interspersed between the fibroblast cells. Some area of fibrin rich clot and coagulum invaded by neutrophils and macrophages were present on superficial surface and tissue distant from edges (Fig-3). The epidermis adjacent to wound edge showed hyperplasia.

The wound treated with Betadine solution showed similar type of histopathological picture with almost same degree of fibroblast proliferation, neo-vascularization and re-epithelialization. 25% and 50% *Aloe vera* juice treated cases showed more marked infiltration of fibroblast cells and mononuclear cells as compared to the Betadine as well as NSS treated cases. The collagen fibres in these groups were also thin, fine and dispersed and were comparatively more than the Betadine and NSS treated wounds. The collagen fibre in these groups were also thin, fine and dispersed and were comparatively more than the Betadine and NSS treated wounds (Fig-3). But in the case of 5% *Aloe vera* treated wound, the fibroblast cell were found to be maximum as compared to all other groups, the collagen fibres were thick, dense, wavy, and maximum in number in this groups.

Histological analysis revealed that *Aloe vera* treated wounds, response up to 6th day indicating the fibroblast stimulating activity. A similar dose dependent activity of *Aloe vera* juice has been reported previously [5].

3.2) 12th days

Table-4

Histopathological analysis on 12th day of *Aloe vera* application on excision wound in albino mice.

Parameter	NSS	Betadine	5% (v/v)	25% (v/v)	50% (v/v)	Analysis of result
Collageniza-tion	2.16± 0.0999	2.352± 0.0795	4.034±0.10 8	3.082± 0.1106	2.205±0.1 11	Significant
Epithelializ-ation	2.12± 0.0752	2.084± 0.0640	2.152±0.09 6	2.172± 0.1196	2.167±0.0 96	Non- Significant

Table-5

Analysis of variance showing effect of *Aloe vera* on histopathological finding in excision wound at 12th day.

Source of variance	df	Collagenization		
		SS	MS	F
Between group	4	15.40	3.850	60.64**
Errors	25	1.587	6.3496 E-02	
Total	29	16.99		

Table-6 Analysis of variance (ANOVA)

Source of variance	df	Epithelialization		
		SS	MS	F
Between group	4	2.9833E-02	7.4583E-02	0.150
Errors	25	1.241	4.9639E-02	
Total	29	1.271		

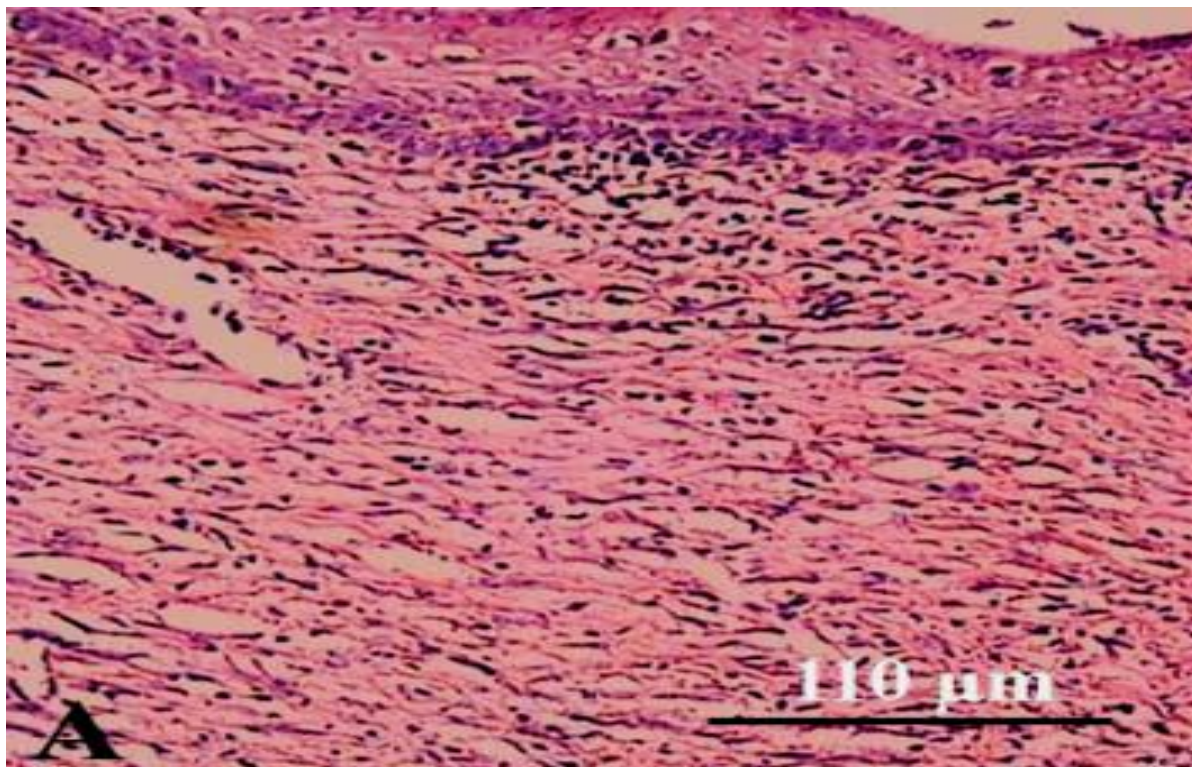
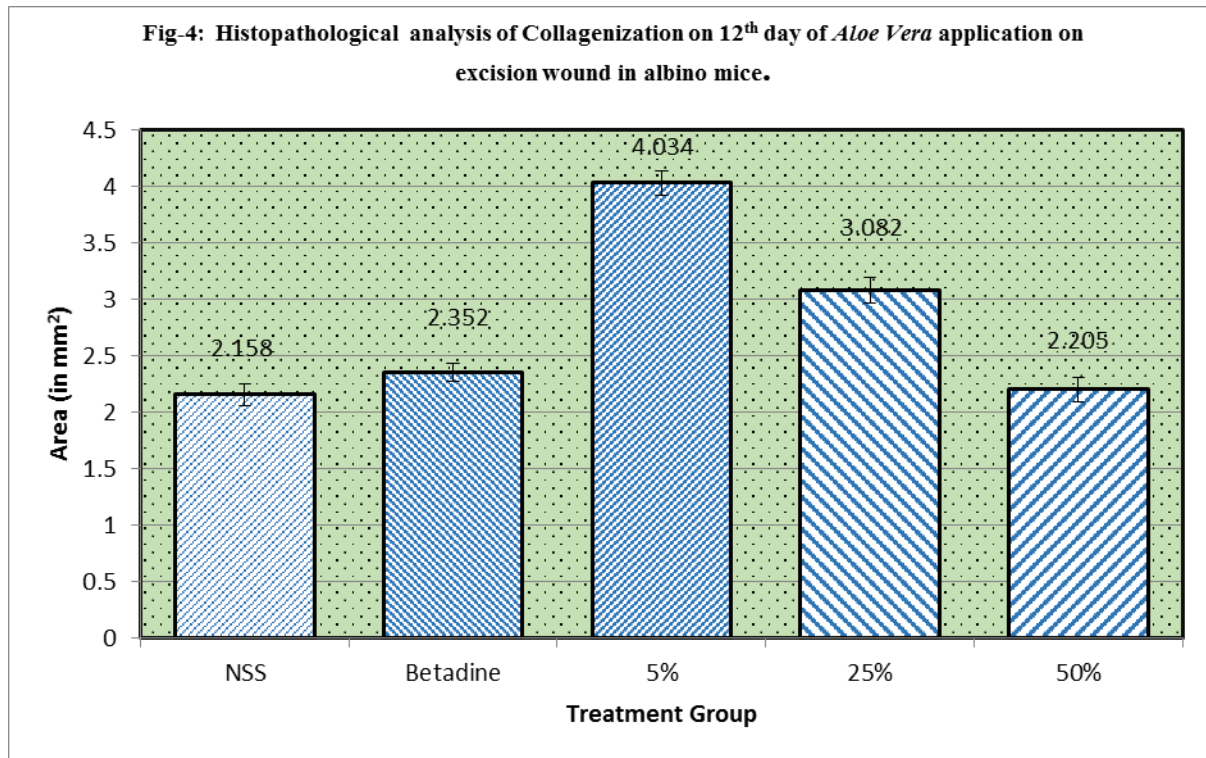


Fig 4: Untreated lesion on 12th day post injury. Re-epithelialization is well developed but cornification has not yet taken place. The number of blood vessels is fewer than those of the treated lesions on 12th day post-injury

and in comparison to those of the untreated lesions on 6th day post injury. Many mononuclear inflammatory cells have infiltrated between the collagen fibers of the dermis (H&E, ×180).

On 12th days of wound creation the microscopic examination of the wound tissue collected and kept as control showed marked increase in collagen accumulation and fibroblast cell proliferation with the newly formed blood vessels. The fibroblast cell was still swollen, plumped and oval. Collagen fiber was also thin, fine and intermixes with the matrix (Fig-4).

The microscopic examination of *Aloe Vera* juice treated wounds showed increase in the maturity of granulation tissue maximum in 5% treated wound. There is less prominent nuclei of fibroblast cells, more thick, dense and wavy collagen bundles, comparatively less number of newly formed blood vessels and lesser number of mononuclear cell infiltration (Fig-4).

On 12th days, synthesis of mature, thick and dense collagen, was observed in *Aloe vera* treated wound having maximum with 5% (Fig-4) followed by 25% and 50% as compared to Betadine and NSS. This is supported by the indirect finding of [4] where enzyme needed for maturation of collagen was estimated to be maximum on 12th day of treatment of *Aloe vera* juice.

In the similar way, the present study show that comparatively higher neo-vascularisation resulted in the *Aloe vera* treated wound, maximum with 5% as compared to the other group. Higher accumulation of reticulin and elastin fiber were found in the *Aloe vera* treated with 5% and 25% as compared to that Betadine, and NSS (control) treated wound. This increase might have associated with the elasticity of the growing tissue, desirable in the wound healing. This has been supported by [7]. He observed that mannose-6-phosphate, a constituent of *Aloe vera* juice, has positive wound healing effect on excision wound in albino mice. *Aloe vera* juice in rats enhances the wound contraction and shortens the period of epithelialization as compared to control group as reported by [16]. As per report of [15], the wound contraction may be due to the contractile property of the modified fibroblast (myofibroblast). Contraction was observed to be maximum with 5%, *Aloe vera* treated on 12th day of wound creation in the present study.

It is due to the presence of mannose-6-phosphate, a constituent of *Aloe vera* juice, which exhibit positive wound healing effect.

III. CONCLUSION

Aloe vera juice in mice enhances the wound contraction and shortens the period of epithelialization as compared to control group. The wound contraction may be due to the contractile property of the modified fibroblast (myofibroblast). Contraction was observed to be maximum with 5%, *Aloe vera* treated on 12th day of wound creation in the present study.

3.1 Author's Statements

Competing interests

The authors declare no conflict of interest.

REFERENCES

- [1] Begum, D., Nath, S.C., (2000). Ethnobotanical review of medicinal plants used for skin diseases and related problems in Northeastern India, *Journal of Herbs. Spices and Medicinal Plants* 7: 55–93.
- [2] Buffoni, F., Bancheli, G., Cambi, S., Ignesti, G., Irisind, R., Raimondi, L., (1993). Skin wound healing some biochemical parameters in Guinea pig. *J Pharmaceutics and Pharmacology* 45: 784–790.
- [3] Chithra, P., Sajithlal, G.B., Chandrakasan, G., Influence of Aloe vera on collagen characteristics in healing dermal wounds in rats. *Mol Cell Biochem.* 1998; 181:71–76.
- [4] Chithra, P., Sajithlal, G.B., Chandrakasan, G. and Chandrakasan, G., (1998). Influence of Aloe vera on the glycosaminoglycane in the matrix of healing dermal wound in albino mic. *J. Ethnopharmacology*, 59:179-186.
- [5] Davis, R.H., Di Donato, J.J., Hartman, G.M., and Hass, R.C., (1994). “Anti-Inflammatory and Wound Healing Activity of a Growth Substance in Aloe vera”. *Journal of the American Podiatric Medical Association*, Vol. 84, No. 2, pp. 77-81
- [6] Diegelmann, R.F., Evans, M.C. Wound healing: an overview of acute, fibrotic and delayed healing. *Front Biosci* 2004; 9:2839.
- [7] Gupta, V.K., Malhotra, S., (2012). Pharmacological attribute of Aloe vera: Revalidation through experimental and clinical studies. *Ayu* 33: 193-196.
- [8] Gunde, M.C., Meshram, S.S., Dangre, P.V., Amnerkar, N.D., (2013). Wound Healing Properties of Methanolic Extract of Seeds of *Mucuna Pruriens*. *International Journal of Pharmacognosy and Phytochemical Research.* 5(1); 57-59.
- [9] Khorasani, G., Hosseinimehr, S.J., Azadbakht, M., Zamani, A., Mahdavi, M.R., (2009). Aloe versus silver sulfadiazine creams for second-degree burns: a randomized controlled study. *Surg. Today*, 39(7): 587-591.
- [10] Martin, P., 1997. Wound healing aiming for perfect skin degeneration. *Science.* 75–81p.
- [11] Pierce, G., Mustoe, T.A., (1995). Pharmacologic enhancement of wound healing. *Annual Review of Medicine*
- [12] 46: 467–481.
- [13] Little, J.W., (2004). Complementary and alternative medicine: impact on dentistry. *Oral Surg Oral Med Oral Pathol Oral Radiol Endod.* 98:137–145.
- [14] Trombetta, D., Puglia, C., Perri, D., Licata, A., Pergolizzi, S., Lauriano, ER. Effect of polysaccharides from *Opuntia ficus-indica* (L.) cladodes on the healing of dermal wounds in the rat. *Phytomedicine.* 2006; 3:352–358
- [15] Reynolds, T., Dweck A.C., Aloe vera leaf gel: a review update. *J Ethnopharmacol.* 1999; 68:3–37.
- [16] Singh, H. and Singh, k., (1999). *Ruminant surgery*, Edited by R.P.S. Tyagi and Jit Singh. CBS Publishers and Distributors, 58-71.
- [17] 16. Udapa, S.L., Udapa, A.L. and Kulkarni, D.R., (1994). Anti-inflammatory and wound healing properties of Aloe vera. *Fitoterapia*, 65(2) 119-123.